

From the textbook
"Essentials of Skeletal Radiology: Volume Two" by Yochum & Rowe

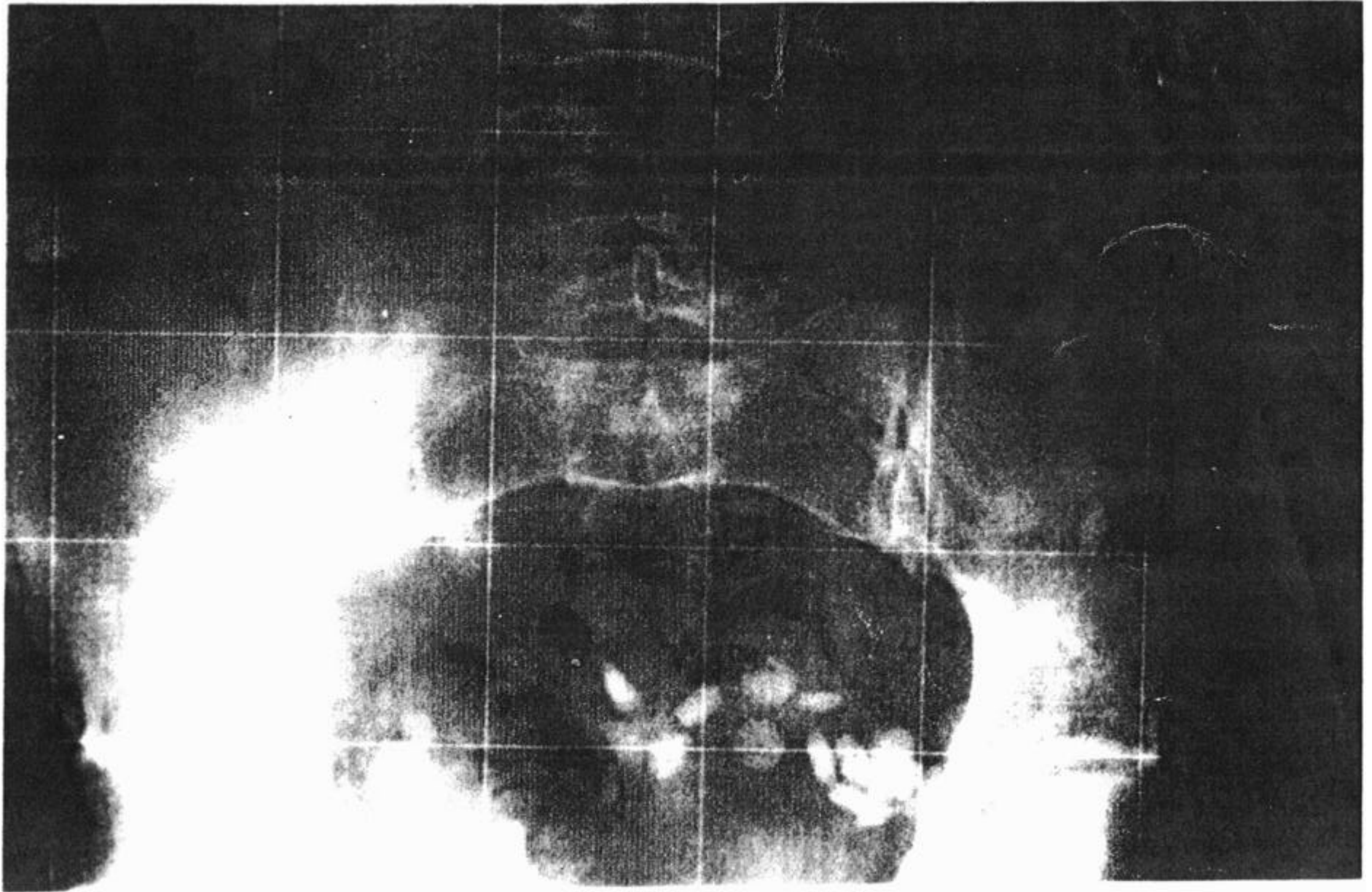


Figure 16.111 This patient has multiple undissolved pills within the bowel.